



## Unilateral septic arthritis of a lumbar facet joint secondary to acupuncture treatment - a case report

Sachin Daivajna, Alwyn Jones, Michael O'Malley, et al.

*Acupunct Med* 2004 22: 152-155

doi: 10.1136/aim.22.3.152

---

Updated information and services can be found at:

<http://aim.bmj.com/content/22/3/152>

---

### Email alerting service

*These include:*

Receive free email alerts when new articles cite this article. Sign up in the box at the top right corner of the online article.

---

### Notes

---

To request permissions go to:

<http://group.bmj.com/group/rights-licensing/permissions>

To order reprints go to:

<http://journals.bmj.com/cgi/reprintform>

To subscribe to BMJ go to:

<http://journals.bmj.com/cgi/ep>

# Unilateral septic arthritis of a lumbar facet joint secondary to acupuncture treatment - a case report

Sachin Daivajna, Alwyn Jones, Michael O'Malley, Hossein Mehdian

Sachin Daivajna  
visiting fellow

Alwyn Jones  
spinal fellow

Michael O'Malley  
spinal fellow

Hossein Mehdian  
spinal consultant  
Centre for Spinal Studies  
and Surgery  
University Hospital,  
Nottingham, UK

Correspondence:  
Alwyn Jones

[alwyn.j@virgin.net](mailto:alwyn.j@virgin.net)

## Summary

This report describes a case of septic arthritis of the lumbar facet joint probably as a result of acupuncture treatment. A 48 year old man with a long history of back pain presented with a two week history of increasing pain following a third session of acupuncture. Examination revealed tenderness in the right lumbosacral area and laboratory investigations revealed raised inflammatory markers with negative blood cultures. A bone scan and MRI scan showed evidence of septic arthritis of the right L5/S1 facet joint. An x ray computed tomography guided biopsy was carried out which isolated staphylococcus aureus. The patient was initially treated with intravenous antibiotics. A repeat MRI scan demonstrated persistent septic arthritis with adjacent early abscess formation. Surgical debridement of the facet joint was therefore performed. The patient had resolution of his symptoms and the inflammatory markers returned to normal. He regained a full range of movement of the lumbar spine. Very few cases have been reported of lumbar facet joint septic arthritis and this condition is rare in association with acupuncture treatment. A high index of suspicion needs to be maintained and if conservative management fails then debridement can result in an acceptable outcome.

## Keywords

*Lumbar spine, facet joint, septic arthritis, acupuncture.*

## Introduction

Septic arthritis of the facet joint is an uncommon synovial infection with few cases having been reported in literature.<sup>1-11</sup> The clinical course of this infection is indolent as radiographic changes appear late in the disease and can give rise to severe complications, such as epidural,<sup>12,13</sup> and paraspinal abscesses.<sup>14-17</sup> Though a haematogenous focus is the commonest cause of this infection, it can also arise from an exogenous source such as needles.<sup>2,14,18</sup> The diagnosis of this infection requires a high index of suspicion, as it mimics degenerative disc disease or spondylolysis. The condition usually affects older people, but there are reports in the younger age group as well.<sup>18,19</sup> Recently, there have been reports of facet joint infection due to facet injections,<sup>2</sup> and acupuncture.<sup>15</sup> This is the second report of acupuncture causing septic arthritis of a facet joint in the literature. The purpose of this report is to emphasise the need for clean conditions when acupuncture is performed and to highlight the difficulties in diagnosis and management of facet

joint infection.

## History

A 48 year old patient with a long history of back pain had received three treatment sessions of acupuncture for back pain when he recalled at the final session a needle being inserted deeply into the right lumbosacral area. Three days following this, he developed increasing lumbar pain, which became severe over a two-week period. This was associated with malaise and fever. Unfortunately, the experience of the acupuncturist, the length of needles used and the precise acupuncture points used are not known. The patient was diagnosed in the rheumatology department as having inflammatory arthropathy with pain localised to the right lumbar region and treated with non-steroidal anti-inflammatory drugs. His pain increased, became continuous in nature and began disturbing his sleep.

He was referred to our unit where further questioning revealed that he had received a deep acupuncture needle insertion at the site of the discomfort a few days prior to the onset of pain.

He did not complain of any radicular symptoms either before or after the acupuncture treatment.

### Examination and investigations

Clinical examination revealed a mild fullness in the right lumbar region with gross restriction in lumbar spine movements. There was obvious tenderness around the right lumbo-sacral area on deep palpation but there were no signs of superficial infection. There was no neurological abnormality in either lower limb but he was noted to be pyrexial.

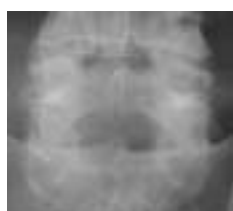

Figure 1 Plain radiograph of the spine demonstrating no obvious abnormality.

Laboratory investigations revealed a rise in white cell count and inflammatory markers (erythrocyte sedimentation rate and C-reactive protein) on admission, which had increased during his hospital stay. Blood and urine cultures were negative. Plain radiographs of the spine were normal (Figure 1). A bone scan and single photon emission computerised tomography (SPECT) scan revealed an area of increased activity at the right L5/S1 facet joint (Figure 2). Magnetic resonance imaging (MRI) revealed increased signal intensity on the T2-weighted sequence at the right L5/S1 facet joint and lower paraspinal region suggesting an infective process (Figure 3).

Biopsy guided by x ray computed tomography (CT) was carried out to confirm the diagnosis of infection and establish a causative organism. The

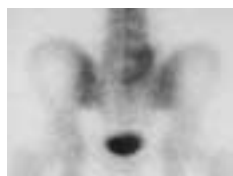

Figure 2 Bone scan demonstrating increased activity around the right L5/S1 facet joint and surrounding tissues.

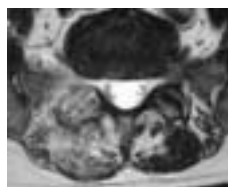


Figure 3 MRI scan demonstrating increased signal in the facet joint and paraspinal muscles.

aspiration of the joint fluid yielded positive cultures for staphylococcus aureus, which was sensitive to flucloxacillin and fusidic acid.

### Treatment and outcome

The patient was started on intravenous antibiotics for three weeks with resolution of his pain and malaise. The inflammatory markers did not settle and therefore a repeat MRI scan was performed which revealed persistence of the infection with abscess formation and epidural spread (Figure 4). The decision was made to perform a surgical debridement and biopsy of the facet joint. At operation, obvious infected tissue with abscess formation was identified involving the facet joint and surrounding tissues. These tissues were debrided with lavage of the epidural space. Postoperatively the patient continued his antibiotic regime, which comprised three weeks of intravenous, followed by three weeks of oral antibiotics.

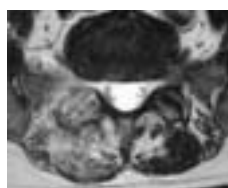


Figure 4 MRI scan demonstrating abscess formation in the paraspinal muscles around the abnormal facet joint with signal change in the epidural space.

The patient had resolution of his symptoms and the inflammatory markers returned to normal. He regained a full range of movement of the lumbar spine.

### Discussion

Septic arthritis of the lumbar facet joint is a rare condition with few reports in the literature. It

usually occurs following haematogenous spread but can occur following direct inoculation of the joint. This case was a rare presentation of unilateral facet joint infection probably secondary to acupuncture treatment. It presented as an acute exacerbation of chronic low back pain, which mimicked an inflammatory arthropathy.

The pathological changes of facet joint infection involve destruction of the synovial joint surfaces and breach of the capsule. The infection can then spread causing a paraspinal abscess or an epidural space collection. Patients with facet joint septic arthritis generally present with subtle signs of fever and malaise associated with atypical lumbar pain. It may present as isolated back pain or it may become radicular. Radiation to the leg suggests nerve root irritation or impending spread of the infection into the epidural space. The duration of onset of symptoms may vary from two days to five months in some series.<sup>1</sup> The infective organisms are usually staphylococcus aureus,<sup>10</sup> staphylococcus epidermidis, group B streptococcus, salmonella or E. coli.<sup>19-21</sup>

The inflammatory markers are raised in all cases. The most reliable markers have been the erythrocyte sedimentation rate and C-reactive protein.<sup>1,5,12</sup> A routine blood culture helps to confirm a systemic or haematogenous cause but an image-guided biopsy may be required when blood cultures are negative. Plain radiographs tend to be normal in early infection as was seen in this case.<sup>1,5,11,13,23</sup> It takes a few weeks for radiographic changes of osteomyelitis to appear, which include juxtarticular osteoporosis and bony erosion.<sup>10</sup> A technetium scan is a highly sensitive test to detect facet infection as early as three days after the onset of symptoms.<sup>4</sup> However, Gallium-67 scan, which is more specific in spondylodiscitis, may be falsely negative in early cases of facet joint infections,<sup>23</sup> while an MRI scan is both sensitive and specific in detecting infection as early as two days from the onset of symptoms.<sup>6,24</sup> This scan provides accurate information regarding the extent of facet destruction and detects any abnormal epidural fat signal (impending epidural abscess). Paraspinal extension of infection can also be seen in detail. CT scans are not as sensitive in the early stages when bony destruction has not yet taken place,<sup>6</sup> but CT can be used to assist in image-

guided biopsies. SPECT scans can also help localise the findings of the bone scan and confirm involvement of the facet joint.<sup>22</sup>

The primary treatment for these infections is conservative using intravenous antibiotics.<sup>24,25</sup> Monitoring of inflammatory markers assesses the response of the infection to treatment. In our case there was little decrease in the erythrocyte sedimentation rate or C-reactive protein, which suggested persistent infection or the presence of an abscess. In these circumstances a repeat MRI is worthwhile. In patients who do not respond to conservative management, the disease process must be monitored closely and surgical debridement or an open biopsy considered. This would allow definitive tissue acquisition and formal drainage of any resulting abscess.

Acupuncture can cause infection if clean conditions are not adhered to. Previous reports have highlighted infections as a result of facet joint injections.<sup>2</sup> Only one previous report was found of septic arthritis of a facet joint secondary to acupuncture.<sup>15</sup> There has been a similar report of sacroiliac infection resulting from acupuncture in the literature.<sup>18</sup> These reports recommended improved precautions against infection.

With the increasing use of acupuncture, there are increasing reports of associated complications, one of which is septic arthritis of the facet joint. A high index of suspicion is therefore necessary when faced with a patient with increasing pain following acupuncture treatment. We have presented a case where deep acupuncture treatment for back pain seems to have been responsible for an underlying facet joint infection. Aseptic conditions for acupuncture needle insertion are probably unrealistic and unnecessary but we would advise that treatments are performed under clean conditions to minimise the risk of the above complication.

#### Reference list

1. Alcock E, Regaard A, Browne J. Facet joint injection: a rare cause of epidural abscess formation. *Pain* 2003; 103(1-2):209-10.
2. Baker AS, Oj Gemann RG, Swartz MN, Richardson EP Jr. Spinal epidural abscesses. *N Engl J Med* 1975; 293(10):463-8.
3. Cecil M, Dimar JR 2nd. Paraspinal pyomyositis, a rare cause of severe back pain: case report and review of the literature. *Am J Orthop* 1997;26(11):785-7.
4. Doita M, Nishida K, Miyamoto H, Yoshiya S, Kurosaka

- M, Nabeshima Y. Septic arthritis of bilateral lumbar facet joints: report of a case with MRI findings in the early stage. *Spine* 2003; 28(10):E198-202.
5. Eismont FJ, Bohlman HH, Soni PL, Goldberg VM, Freehafer AA. Pyogenic and fungal vertebral osteomyelitis with paralysis. *J Bone Joint Surg Am*. 1983;65A(1):19-29.
  6. Hadjipavlou AG, Cesani-Vasquez F, Villanueva-Meyer J, Mader JT, Necessary JT, Crow W, et al. The effectiveness of gallium citrate Ga-67- radionuclide imaging in vertebral osteomyelitis revisited. *Am J Orthop* 1998; 27(3):179-83.
  7. Peris P, Brancos MA, Gratacos J, Moreno A, Miro JM, Munoz J. Septic arthritis of spinal apophyseal joint; report of two cases and review of literature. *Spine* 1992; 17(12):1514-16.
  8. Pilleul F, Garcia J. Septic arthritis of the spine facet joint; early positive diagnosis on magnetic resonance imaging. Review of two cases. *Joint Bone Spine* 2000;67(3):234-7.
  9. Roberts WA. Pyogenic vertebral osteomyelitis of a lumbar facet joint with associated epidural abscess: A case report with review of the literature. *Spine* 1988;13(8):948-52.
  10. Rombauts PA, Lindenx PM, Buyse AJ, Snoecx MP, Lysens RJ, Gryspeerdt SS. Septic arthritis of a lumbar facet joint caused by *Staphylococcus aureus*. *Spine* 2000; 25(13):1736-8.
  11. Sapico FL, Montgomerie JZ. Pyogenic vertebral osteomyelitis: report of nine cases and review of the literature. *Rev Infect Dis* 1979;1(5):754-76.
  12. Calderone RR, Larsen JM. Overview and classification of spinal infections. *Orthop Clin North Am* 1996;27(1):1-8.
  13. Heenan SD, Britton J. Septic arthritis in a lumbar facet joint: rare cause of an epidural abscess. *Neuroradiology* 1995;37(6):462-4.
  14. Ishibe M, Inoue M, Saitou K. Septic arthritis of a lumbar facet joint due to pyonex. *Arch Orthop Trauma Surg* 2001;121(1-2):90-92.
  15. Laing AJ, Mullett H, Gilmore MF. Acupuncture-associated arthritis in a joint with an orthopaedic implant. *J Infect* 2002;44(1):43-4.
  16. Marson F, Cognard C, Guillem P, Sevely A, Manelfe C. Septic arthritis of a lumbar facet joint associated with epidural and paravertebral soft tissue abscess. *J Radiol* 2001;82(1):63-6.
  17. Leibergall M, Chaimsky G, Lowe J, Robin GC, Floman Y. Pyogenic vertebral osteomyelitis with paralysis; prognosis and treatment. *Clin Orthop* 1991;269:142 -150.
  18. Lau SM, Chou CT, Hauang CM. Unilateral sacroiliitis as an unusual complication of acupuncture. *Clin Rheumatol* 1998;17(4):357-8.
  19. Darouiche RO, Hamill RJ, Greenberg SB, Weathers SW, Musher DM. Bacterial spinal epidural abscess: review of 43 cases and literature survey. *Medicine (Baltimore)* 1992;71(6):369-85.
  20. Dauwe DM, Vano Oyen JJ, Samson IR, Hoogmartens MJ. Septic arthritis of a lumbar facet joint and a sternoclavicular joint. *Spine* 1995;20(11):1304-6.
  21. Fujiwara A, Tamai K, Yamato M, Yoshida H, Saotome K. Septic arthritis of a lumbar facet joint: report of a case with early MRI findings. *J Spinal Disord* 1998;11(5):452-3.
  22. Swayne LC, Dorsky S, Caruana V, Kaplan IL. Septic arthritis of a lumbar facet joint: detection with bone SPECT imaging. *J Nucl Med* 1989;30(8):1408-11.
  23. Hall RL, Callaghan JJ, Moloney E, Martinez S, Harrelson JM. Polyomyositis in a temperate climate: presentation, diagnosis and treatment. *J Bone Joint Surg Am* 1990;72(8)A:1240-4457-9.
  24. Muffoletto AJ, Ketonen MD, Kenton LM, Mader JTT, Crow WN, Hadjipavlou AG. Haematogenous pPyogenic Ffacet Jjoint Iinfection. *Spine* 2001;26(14):1570-1576.
  25. Halpin DS, Gibson RD. Septic arthritis of a lumbar facet joint. *J Bone Joint Surg Br* 1987;69(3)B:457-9.